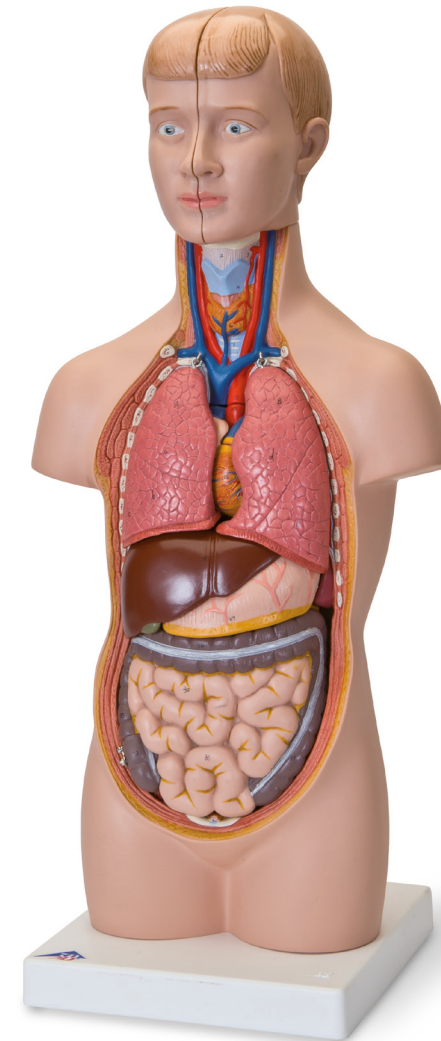




...going one step further



B22 (1000195)-09/17-2



3B Scientific

A worldwide group of companies

3B Scientific GmbH • Customer Service Medical
Rudorffweg 8 • 21031 Hamburg • Germany
Phone: + 49 (0)40-73966-0 • Fax: + 49 (0)40-73966-100
3bscientific.com • info@3bscientific.com

© Copyright 2016 for instruction manual and design of
product: 3B Scientific GmbH, Germany

5001955

B22

(1000195)

Latin

CAPUT

- 1 Os frontale
- 2 Os sphenoidale
- 3 Os parietale
- 4 Os temporale
- 5 Os occipitale
- 6 Sinus frontalis
- 7 Os nasale
- 8 Maxilla
- 9 Mandibula
- 10 Cerebrum
- 11 Cerebellum

REGIO CERVICALIS

- 1 Os hyoideum
- 2 Ligamentum thyrohyoideum medianum
- 3 Membrana thyrohyoidea
- 4 Cartilago thyroidea
- 6 GLANDULA THYROIDEA
- 7 Cartilagine tracheales

CAVITAS THORACIS

COR

- 9 Ventriculus sinister
- 10 Pars ascendens aortae
- 11 Valva aortae
- 12 Arcus aortae
- 12a Pars thoracica aortae
- 12b Pars abdominalis aortae
- 13 Atrium sinistrum
- 14 Auricula sinistra
- 15 Valva atrioventricularis sinistra (Valva mitralis)
- 16 Ventriculus dexter
- 17 Truncus pulmonalis
- 18 Valva trunci pulmonalis
- 19 Atrium dextrum
- 20 Auricula dextra
- 21 Vena cava superior
- 22 Vena cava inferior
- 23 Valva atrioventricularis dextra (Valva tricuspidalis)
- 24 Venae pulmonales

- 25 Bifurcatio tracheae
- 26 Bronchus principalis dexter
- 27 Bronchus principalis sinister
- 28 Bronchus segmentalis

A PULMO DEXTER

- a Lobus superior
- b Lobus medius
- c Lobus inferior

B PULMO SINISTER

- d Lobus superior
- e Lobus inferior

34 Oesophagus

35 Diaphragma

CAVITAS ABDOMINIS

- 1 SPLEN
- 2 REN DEXTER
- 6 Arteria renalis
- 7 GLANDULA SUPRARENALIS SINISTRA
- 8 REN SINISTER
- 9 Ureter sinister
- 10 VESICA URINARIA
- 11 HEPAR
- a Lobus hepatis dexter
- b Lobus hepatis sinister
- 14 Lobus quadratus
- 15 Lobus caudatus
- 16 Arteria hepatica communis
- 17 Vena portae hepatis
- 18 Ductus hepaticus communis
- 19 Ductus cysticus
- 20 VESICA BILIARIS
- 22 GASTER
- 23 Cardia
- 24 Fundus gastricus
- 25 Pylorus
- 26 Curvatura minor
- 27 Curvatura major
- 28 PANCREAS

INTESTINUM TENUE

- 29 Duodenum
- 30 Jejunum
- 31 Ileum

INTESTINUM CRASSUM

- 32 Caecum
- 33 Appendix vermiformis
- 34 Valva ileocaecalis

COLON

- 35 Colon ascendens
- 36 Colon transversum
- 37 Colon descendens
- 38 Colon sigmoideum
- 39 Rectum

Mini-torso

HEAD

- 1 Frontal bone
- 2 Sphenoidal bone
- 3 Parietal bone
- 4 Temporal bone
- 5 Occipital bone
- 6 Frontal sinus
- 7 Nasal bone
- 8 Maxilla
- 9 Mandible
- 10 Cerebrum
- 11 Cerebellum

NECK REGION

- 1 Hyoid bone
- 2 Median thyrohyoid ligament
- 3 Thyrohyoid membrane
- 4 Thyrohyoid cartilage
- 6 THYROID GLAND
- 7 Tracheal cartilage

THORACIC CAVITY

HEART

- 9 Left ventricle
- 10 Ascending aorta
- 11 Aortic valve
- 12 Arch of aorta
- 12a Thoracic aorta
- 12b Abdominal aorta
- 13 Left atrium
- 14 Left auricle
- 15 Mitral valve
- 16 Right ventricle
- 17 Pulmonary trunk
- 18 Pulmonary valve
- 19 Right atrium
- 20 Right auricle
- 21 Superior vena cava
- 22 Inferior vena cava
- 23 Tricuspid valve
- 24 Pulmonary veins

- 25 Tracheal bifurcation
- 26 Right main bronchus
- 27 Left main bronchus
- 28 Segmental bronchus

A RIGHT LUNG

- a Superior lobe
- b Middle lobe
- c Inferior lobe

B LEFT LUNG

- d Superior lobe
- e Inferior lobe

34 Oesophagus

35 Diaphragm

ABDOMINAL CAVITY

- 1 SPLEN
- 2 RIGHT KIDNEY
- 6 Renal artery
- 7 LEFT SUPRARENAL GLAND
- 8 LEFT KIDNEY
- 9 Left ureter
- 10 URINARY BLADDER
- 11 LIVER
- a Right lobe of liver
- b Left lobe of liver
- 14 Quadrate lobe
- 15 Caudate lobe
- 16 Common hepatic artery
- 17 Hepatic portal vein
- 18 Common hepatic duct
- 19 Cystic duct
- 20 GALLBLADDER
- 22 STOMACH
- 23 Cardiac
- 24 Fundus of stomach
- 25 Pylorus
- 26 Lesser curvature
- 27 Greater curvature
- 28 PANCREAS

SMALL INTESTINE

- 29 Duodenum
- 30 Jejunum
- 31 Ileum

LARGE INTESTINE

- 32 Caecum
- 33 Appendix, Vermiform appendix
- 34 Ileoaeal valve

COLON

- 35 Ascending colon
- 36 Transverse colon
- 37 Descending colon
- 38 Sigmoid colon
- 39 Rectum

English

Deutsch

KOPF

- 1 Stirnbein
- 2 Keilbein
- 3 Scheitelbein
- 4 Schläfenbein
- 5 Hinterhauptbein
- 6 Stirnhöhle
- 7 Nasenbein
- 8 Oberkiefer
- 9 Unterkiefer
- 10 Großhirn
- 11 Kleinhirn

HALSREGION

- 1 Zungenbein
- 2 Mittl. Schildknorpel-Zungenbeinband
- 3 Schildknorpel-Zungenbeinmembran
- 4 Schildknorpel
- 6 SCHILDDRÜSE
- 7 Luftröhrenknorpel

BRUSTHÖHLE

HERZ

- 9 Linke Herzkammer
- 10 Aufsteigende Hauptschlagader
- 11 Aortenklappe
- 12 Aortenbogen
- 12a Brustaaorta
- 12b Bauchaaorta
- 13 Linker Vorhof
- 14 Linkes Herzohr
- 15 Mitralklappe
- 16 Rechte Herzkammer
- 17 Lungenschlagaderstamm
- 18 Pulmonalklappe
- 19 Rechter Vorhof
- 20 Rechtes Herzohr
- 21 Obere Hohlvene
- 22 Untere Hohlvene
- 23 Trikuspidalklappe
- 24 Lungenvenen

- 25 Gabelung der Luftröhre
- 26 Rechter Hauptbronchus
- 27 Linker Hauptbronchus
- 28 Segmentbronchus

A RECHTE LUNGE

- a Oberlappen
- b Mittellappen
- c Unterlappen

Mini-Torso

LINKE LUNGE

- d Oberlappen
- e Unterlappen

34 Speiseröhre

35 Zwerchfell

BAUCHHÖHLE

- 1 MILZ
- 2 RECHTE NIERE
- 6 Nierenarterie
- 7 LINKE NEBENNIERE
- 8 LINKE NIERE
- 9 Linker Harnleiter
- 10 HARNBLASE
- 11 LEBER
- a Rechter Leberlappen
- b Linker Leberlappen
- 14 Viereckiger Leberlappen
- 15 Schwanzförmiger Leberlappen
- 16 Gemeinsame Leberarterie
- 17 Pfortader
- 18 Gemeinsamer Ausführungsgang der Leber
- 19 Ausführungsgang der Gallenblase
- 20 GALLENBLASE
- 22 MAGEN
- 23 Mageneingang
- 24 Magengrund
- 25 Pförtner
- 26 Kleine Krümmung
- 27 Große Krümmung
- 28 BAUCHSPEICHELDRÜSE

DÜNNDARM

- 29 Zwölffingerdarm
- 30 Leerdarm
- 31 Krummdarm
- DICKDARM
- 32 Blinddarm
- 33 Wurmfortsatz
- 34 Bauhinsche Klappe

GRIMMDARM

- 35 Aufsteigender Teil
- 36 Querverlaufender Teil
- 37 Absteigender Teil
- 38 Sigmoid
- 39 Mastdarm